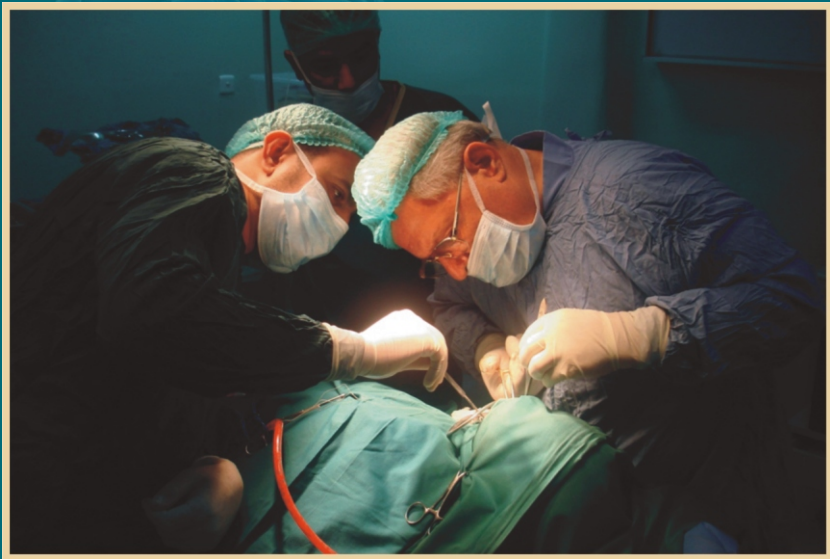

# Disease of the Temporomandibular Joint, Surgical Reconstruction, Clinical & Experimental Studies

Raja Kummoona



**SciencePG**  
Science Publishing Group

Science Publishing Group



# **Disease of the Temporomandibular Joint, Surgical Reconstruction, Clinical & Experimental Studies**

---

**Raja Kummoona**



**SciencePG**  
Science Publishing Group

Science Publishing Group

548 Fashion Avenue  
New York, NY 10018

<http://www.sciencepublishinggroup.com>

Published by Science Publishing Group 2014

Copyright © Raja Kummoona 2014

All rights reserved.

First Edition

**ISBN: 978-1-940366-13-5**

This work is licensed under the Creative Commons  
Attribution-NonCommercial 3.0 Unported License. To view a copy of this  
license, visit

<http://creativecommons.org/licenses/by-nc/3.0/>




or send a letter to:  
Creative Commons  
171 Second Street, Suite 300  
San Francisco, California 94105  
USA

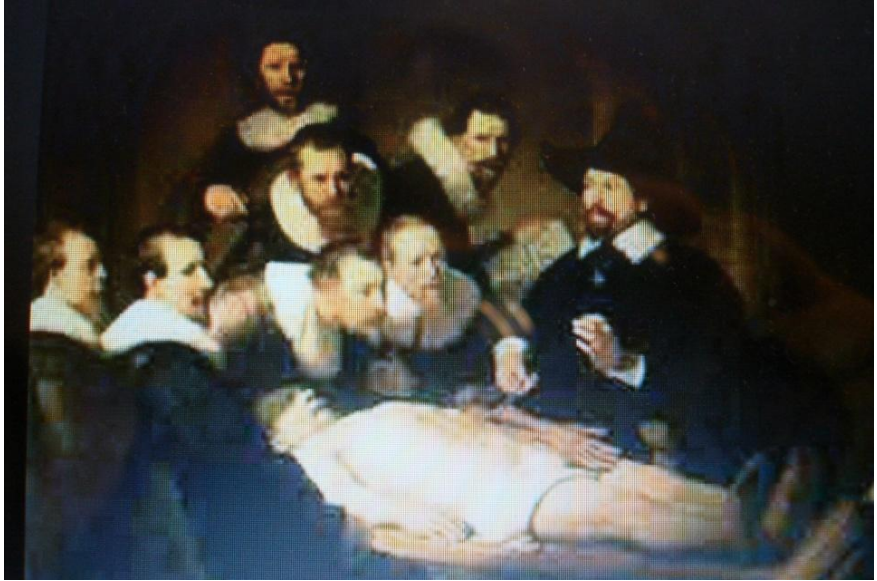To order additional copies of this book, please contact:

Science Publishing Group  
[service@sciencepublishinggroup.com](mailto:service@sciencepublishinggroup.com)  
<http://www.sciencepublishinggroup.com>

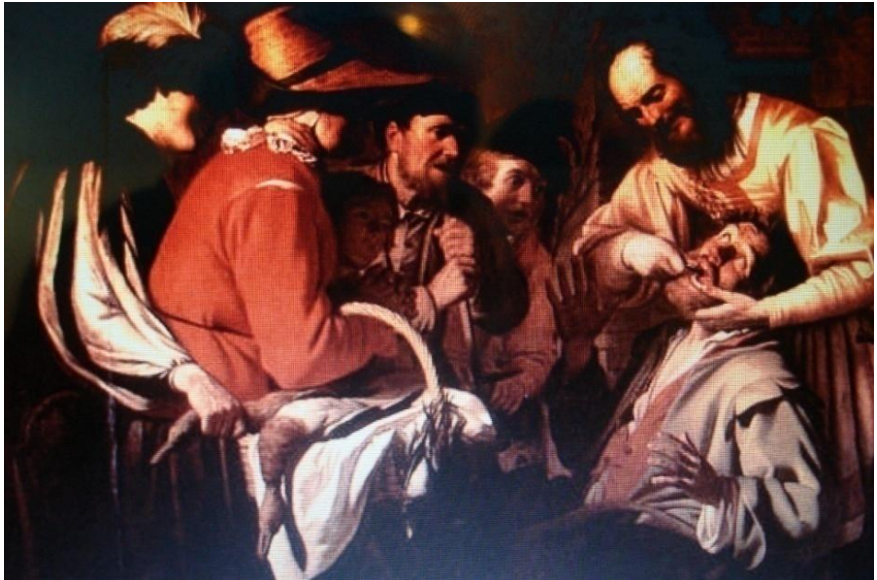Printed and bound in India



*The key for facial deformity is condylar growth disturbance, international paint showing deformity of the face.*

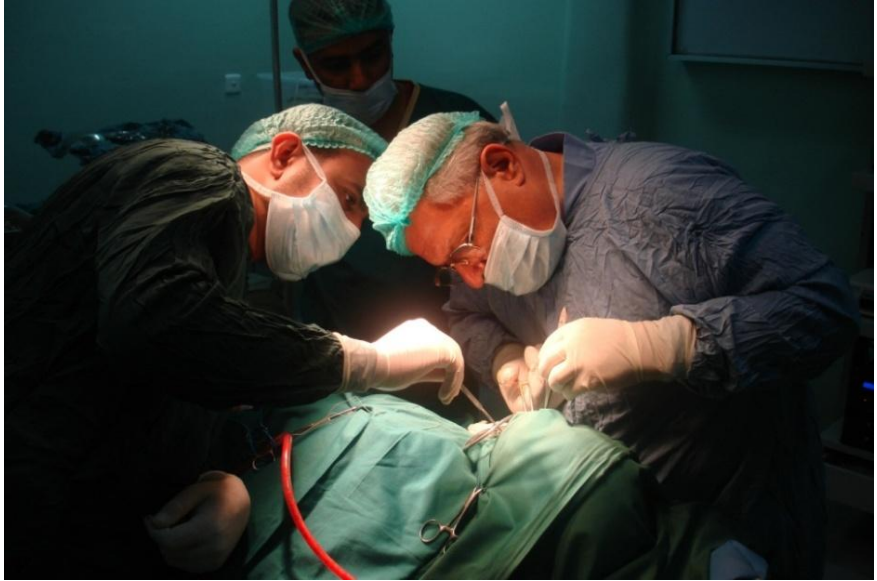

*International paint shows surgical operation carried by eminent surgeons during 17<sup>th</sup> century.*

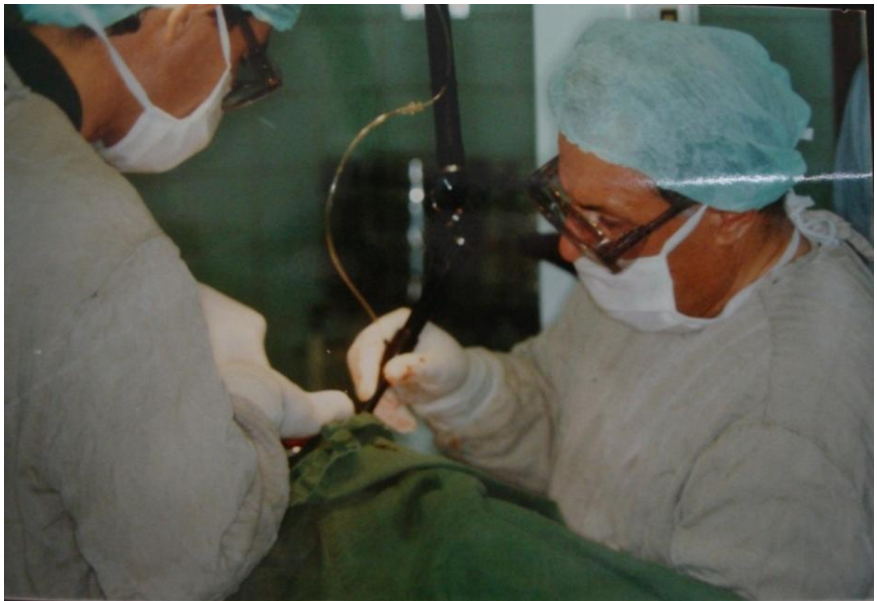

*This paint showing barber practicing and teaching dental surgery as first step for Maxillofacial Surgery progress.*





*Professor Raja Kummoona is operating in the oro- facial region of a child.*



*Professor Raja Kummoona is operating by using CO<sub>2</sub> Laser hand piece for surgical excision of malignant tumor in the oral cavity.*





## Preface

Temporo-mandibular joint (TMJ) disease, surgical reconstruction clinical and experimental studies is a completion of the research conducted in the Royal College of surgeons, England at Down research unite, Orpington, UK for three years (1975-1977) as research Fellow. Experimental studies were carried on *Mecaca Iris* monkeys. Our initial efforts directed towards reconstruction of 2-part prosthesis to solve the problem of suffering patients from masticatory problems due to fix ankylosed TMJ. The aim was to prove the biological inert material of the prosthesis due to presence of chromium oxide film coated the prosthesis, to study the corrosive property of the metal or any changes in color of the metal and functional part of the prosthesis as a good substitute to replace the damaged TMJ, to study also the effect of the implant on the tissue surrounding the prosthesis, and any possibilities of rejection, infection or thrombosis of small vessels surrounding the prosthesis. The directions of clinical application were on young adult patients when the growth of the mandible and mid face already completed. This pioneer work of the author on TMJ was after Sir John Charnely hip replacement.

Our further research was directed to use an autogenous tissue to reconstruct the TMJ for restoration of function and growth of the condyle, mandible and mid face in children. Our best choice was the chondro-ossous graft instead of costo-chondral graft with certain objection about application of this graft clinically and to support this new technique by experimental studies on Rabbits for study the viabilities of the graft and its ability to withstand the force of masticatory process and restoration of normal growth of the mandible and midface. There was no any evidence of chondro-fication or ossification of the graft and the first clinical report was published 1986. This technique is the most popular one nowadays for reconstruction of the condyle worldwide.

During my visit to Yemen 1998 to the university of science and

technology as visiting professor, many cases were referred to me, patients were complaining from recurrent chronic subluxation featuring unstable mandible with difficulties in speech mastication and inability to control the jaw during examination of these cases due to shaking and instability of the mandible, we found complete damages of the TMJ structures with flat glenoid fossa, atrophy of articular eminence, lax capsule, TMJ ligaments and osteoarthritis of the condyle, these signs were noticed due to daily chewing Qat for several hours changing the passive movements of the TMJ to active movements with great load exerted on the TMJ. This situation made me to think and advocate a new technique for reconstruction of the TMJ by using a finger-like temporal fascia flap graft of inferiorly based for reconstruction of the anterior and lateral wall of lax capsule for reinforcement of the capsule and bone graft from iliac crest inserted in a gap created by osteotomy to create a defect and the graft impacted in the created defect just anterior to articular eminence in an oblique direction of 45 degree towards the joint as an obstacle to prevent forward movement of the condyle just behind articular eminence. Experimental studies were carried out on Rabbits to observe the viabilities of tissue of the condyle and capsule by using temporal fascia flap technique for reconstruction of the capsule.

Further research carried out recently to study the role of mesenchyme stem cells of the chondro-ossous graft in the growth of the condyle and also to prove it as growth center for continuous remodeling and repair of the condyle after resection of the condyle. This clinical experience gained through hard work for managements of a difficult pathology of the TMJ and many surgical techniques was advocated by the author during the last 40 years was a good guide for many maxillofacial and craniofacial surgeons with lack of experience in this sub specialty. We hope to satisfy our colleagues and friends worldwide by presenting this useful book. This book was divided into many chapters, the first chapter includes, the basic science, about development, anatomy, physiology and growth of the TMJ, the second chapter deals with specification of animal models used for reconstruction of the TMJ, the third chapter dealing with diseases of the TMJ including traumatic, congenital, degenerative, infective, functional and tumors of the TMJ, other chapters deal with surgical reconstructions of subluxation and dislocation of the TMJ, 2-part prosthesis of the TMJ,

chondro-ossous graft of the TMJ and reconstruction of the TMJ by Temporalis' muscle flap and sialastic implant, re eplantation of the condyle after radical resection of the mandible for tumor not involving the condyle and the condyle fixed to bone graft and re implanted. The last chapter was dealing with the mesenchyme stem cells of the chondro-ossous graft transferred from iliac crest to replace the TMJ changing its function from weight bearing in the iliac to masticatory function in the TMJ and its value in the continuous growth of the graft.

We tried to be an up to date in our research and to present to the world the most valuable and informative knowledge to the readers of this book and the value of this book by its content and rich clinical experience gained by the author during the last 40 years.

My thanks to Mr. Anthony Smith and Wency Davis, Book publishing Dept. Science Publishing Group for their kind assistant in preparation of this Book.

*--Raja Kummoona*



## History of Maxillofacial Surgery

During the second world war and the evolution of specialised treatment for maxillofacial surgery carried in UK by pioneer work of Sir Harold Gillies and Sir William Kelsy Fry, they put the foundation bases of collaboration between the Medical and Dental services and were able to perform their duties in equally static services and treatment were primarily provided in two levels the front line regimental aid posy and the base hospital.

The success of managements of war injuries in the 2<sup>nd</sup> world war due to close cooperation between the plastic and maxillofacial unite based on plastic surgeon, maxillofacial surgeon and dental laboratory, these unites after the war served civilian people scattered in UK based on industrial area and near to the high way roads to give the best services in road traffic accident with urgent transportation.

Advances of treatment of jaw injury was achieved by the work of Sir Kelsy Fry and his colloquies by advocating Locking Plate System at East Grinstead and introduced a system of individual splint for each fragments with locking plate, further advances in management of jaw injuries by using external pin fixation.

At Rocks down house Hospital, Waknits an American Surgeon was working with a finer type of Pin, applying the Roger-Anderson principle in managements of fractures of the Hand Bones, in conjunction with Rushton Walker an appliance of external pin fixation developed for treatment of mandibular fractures and further improvement of the device done by Walker and Clouston, this technique was of great value before the advent of Penicillin after research of Sir Fleming, 1944 in St Mary's Hospital, further research done by using bone chips graft technique (Rainsford & Mowlen, 1944) were cancellous chip graft were used in place of block graft for enhancing healing.

Further devices advocated by other people such as Brent Hurst clamp which gripped both the outer and inner cortices instead to be inserted in the bone. Maxillary fractures of Le Fort type were treated by extra skeletal fixation after accurately fitting cast metal cap splint cemented to teeth connecting to plaster Paris head cap and followed by Halo frame as light weight frame through median vertical rods with universal joints and cheek wires.

McIndoe 1941 at East Grinstead, Queen Victoria Hospital made major contribution both for understanding the treatment of fractures of middle third of the facial skeleton.

The major advances was made 1942 with the introduction by Adams of concept of internal skeletal fixation by using sub cutaneous suspension, wires passed from holes drilled in the zygomatic bone to support the maxilla or mandible or both with arch bars fixed to the upper and lower teeth.

At the end of second world war advances continue it an increasing demands for maxillofacial specialties to cope with the rapid development of velocity of modern transportation and high way roads, with advances in varieties and wide scope of antibiotics, improvement of anaesthetic technique and radiographic images, the scope of maxillofacial surgery expanded with increases of use of internal fixation as circum- zygomatic suspension wires and the usage of Roberts 1964, small bone plating system with improvements of instrumentation to facilitate surgical managements, the plaster head cape replaced by light weight Halo frame and Berkshire frame applied to outer table of the skull by four specially shaped pin inserted through the cortical plates with vertical rod attached to cap splint and cheek wires and Box frame with 4 external pins with rods and universal joint for urgent cases of Le Fort III was advocated.

The American Army doctors gained great experience from the 2<sup>nd</sup> World War, North Korean war, Vietnam war and Gulf War and did great advances and progress in managements of war injuries by advocating many good procedures, example of using arch bars, eyelet and continuous wires for holding the fractured jaw. Great people of Blair,

Ivy and Converse and Kazan Jian, great surgeons were advanced Maxillofacial and Plastic Surgery. Kazanijian was appointed as the first professor of plastic surgery in Harvard Medical School and he was the first president of ASMS (American Society of Maxillofacial Surgery). Great people in the past were trained with Sir Harold Gillis and became the leaders in Maxillofacial and Plastic Surgery in their own countries and worldwide like Paul Tessier, Converse, Hugo Obwegeser and Tord Skoog and the first book in Maxillofacial Injuries published in mid-fifties in UK by Norman Rowe & H. C. Killey who was in chair of Professor of Oral Surgery, Eastman Dental Hospital after Sir Kelsey Fry death. The first Le Fort III osteotomy was done by Gillis for his nurse, few weeks later; the case relapsed because he didn't insert bone graft at osteotomy site, Paul Tessier, succeeded because he used bone graft.

Oral and Maxillofacial Surgery originated as surgical specialties of Dentistry developed for the need for specialist to treat jaw injuries during and after the 2<sup>nd</sup> World War, the specialty of Oral and Maxillofacial Surgery evolved to meet the clear demand for treatment an increasing large range of pathological condition of the face, jaw and teeth. The Plastic & Maxillofacial unit created in UK and distributed in UK.

The beginning of a Post Graduate Dental qualification with high clinical experience was awarded by the Royal College of Surgeons of England (FDSRCS) after establishment of Faculty of Dentistry in 1947 and before that in RCS Edinburgh 1946, it was the highest qualification in maxillofacial Surgery till mid-eighties of last century, a new qualification of FRCS (Maxillofacial) established in Edinburgh as one of surgical specialties and the highest degree in maxillofacial surgery due to expansion of the field to meet the requirement of Craniofacial, Head & Neck and recently Cosmetic Surgery. The American they kept and insist on Maxillofacial Surgery to be as Dental specialty and they have their own 5-6 years program with Board Certificate.

Mr Norman Rowe establish his unit in Queen Mary's Hospital, Roehampton for higher training in Maxillofacial Surgery and this unit was a centre for training candidate preparing for the final FDSRCS, the highest degree awarded by the RCS, England at that time, I been



honoured to attend his clinic during late 1968 not to learn surgical skill but ethics and manner, also I was attending professor R A Cowsen clinic in Guys Hospital for experience in Oral Medicine and Pathology. My actual training in Maxillofacial Surgery was started in ST Mary's Hospital, Paddington, London but my actual high training in Maxillofacial Surgery as Registrar in ST Luks Hospital, Bradford in Plastic and Maxillofacial unite with Mr Dennis Penney, Mr Tom Barclay and Mr David Crocket, greatly appreciated to those people, they spent a lot of time to teach me, train me and giving me the best.

In the mid-seventies I did spend about three years in the research unite of the RCS, England, Orpington, Kent as Research Fellow with professor David Poswillo, professor of Teratology, this chair created to Poswillo for his advance research in craniofacial deformities' and also with Professor B Cohen Director of the research unite for conducting the experimental studies on Monkeys for total replacement of the TMJ by 2-part chrome cobalt prosthesis as pioneer work in the field. I was lucky to work with Poswillo as a great teacher in experimental studies and experimental pathology, also with close relation with professor H C Killey for advice and friendship till his death 1975.

We started maxillofacial surgery in Iraq in the early seventies by personal effort to request the president AL Baker to order establishment of Maxillofacial unite in Surgical Specialities Hospital, 1978, we did the first training program of 5 years established 1992 with establishment of the first unite of Maxillofacial Surgery, Surgical Specialties Hospital, Medical City, Baghdad in the Arab World, our program more or less similar to American training program and a Council of Maxillofacial Surgery as part of Iraqi Board for Medical Specialization, the training program designed to be combined of Medical and Dental program to award a Board certificate, this training program was discussed for many years by myself with Professor David Poswillo, Professor Sir Paul Bramley from UK and Professor Charles Alling and Professor Vic Matukes from Albama, USA and advice of Professor Hugo Obwegaser of Zurich, since establishment of this studies 90 Maxillofacial surgeons graduated and supervised by me till 2010.

We gained with my colloquies very rich experience in managements of War Injuries during Iraqi-Iranian War, 1980-1988, Gulf war 1991 and war of 2003, I also gained Avery wide experience in managements of missile war injuries and we became a leading surgeons in this field lead to advance surgical managements of missile war injuries worldwide We established Examination Centre by personal effort in 1985 for Primary FDSRCS, Eng. in Iraq, I was the Registrar of this examination, this Examination was supported by Professor Sir Paul Bramely, Dean Faculty of Dental Surgery, Royal College of Surgeons of England and continue to 1990, beside that the responsibilities, all postgraduate studies in Oral Surgery and Oral Medicine that established in the Department of Oral Maxillofacial Surgery including Diploma in Oral Surgery in the beginning of the seventies as a first post graduate studies started in college of Dentistry, while MSc for 2 years program with clinical research thesis in Oral Surgery commenced 1988 and PhD in Oral medicine for candidate holding MSc for 3 years in 1995.

In 1989 Sir Ian Todd, President of the Royal College of Surgeons of England visited Iraq by official invitation to the country, the president and his team invited by me to visit college of Dentistry I had the opportunity to discuss with the President of RCS Sir Ian Todd and his team the training program of Maxillofacial Surgery in our country and in UK and the opportunities to be given to Iraqi candidates and we reached to agreement with the examiners of the college, the Final examination of FDSRCS to be carried in Iraq due to high training of Maxillofacial Surgery but the Certification should be awarded in the college in London, the war of 1990 (Gulf War) spoiled everything and our dreams evaporated.



*Professor Raja Kummoona and Professor Alaa Bashir in the middle at Maxillofacial and Plastic Surgeons meeting of Iraqi Maxillofacial and plastic Surgeons 1996.*

## Introduction

Reconstruction of the Temporo-mandibular joint (TMJ) represent a challenge for all craniofacial and maxillofacial surgeons for the last 4 decades, many disease of the TMJ were not fully understood in the west (like TMJ ankylosis), since they do not see much of these cases as in the Middle east because the standard of health education to understand the basic roles for managements of traumatic injuries of the TMJ is absent.

In the south of Arab land as in Yemen, Somalia and Sudan, people daily habit of chewing Qat which is the main cause for destruction of the TMJ structures featuring, recurrent dislocation and subluxation of the TMJ.

Great advances carried out by pioneers in TMJ surgery to understand the pathogenesis of these destructive disease of the TMJ by advocating many surgical procedures and techniques for reconstruction of the TMJ by using either autogenously tissue or metals such as 2-part prosthesis or sialastic (Rubber Silicon) or temporalis muscle flap for treatment of ankylosis or by using different techniques for managements of subluxation and dislocation including seclerosing materials like STD or by reinforcement by placation of the capsule or by reconstruction of the capsule by finger like temporal fascia flap or making an obstacle by augmentation of the zygomatic root of temporal bone by bone graft from iliac crest. Using Botox A injection to the upper part of lateral petrygoid muscle to delay the action of the muscle connected to the disc, to stabilize the disc and to prevent further movement of the condyle forward behind the articular eminence to prevent clicking of the disc and to prevent unpleasant noises.

Other diseases of the TMJ that required reconstruction such as hemi facial microsomia or first arch dysplasia syndrome and hypoplasia of the condyle, these cases either the TMJ reconstructed by autogenous tissue like costo-chondral graft or by chondro-ossous graft, these two

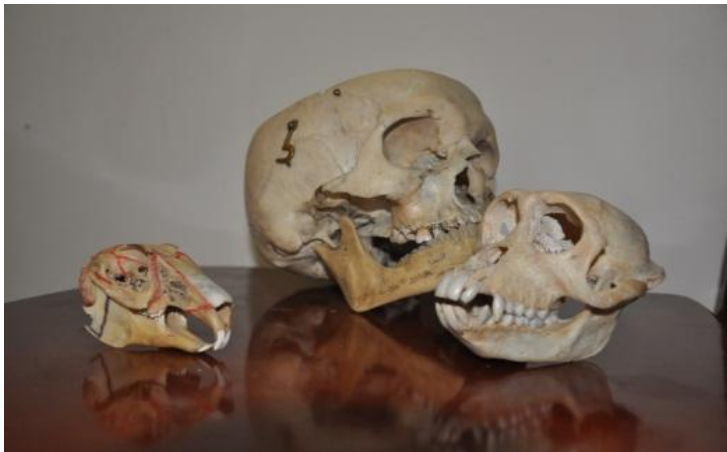procedures were used for managements of ankylosis of the TMJ in children and for reconstruction of the TMJ in other congenital or inquired disease.

In cases of hemi facial microsomia which required a series of operations for correction of cleft of the angle of the mouth, reconstruction the atrophied masseter muscle by platysma muscle flap, removal or excision of tags in front of the ear as remnants of Meckels cartilage followed by reconstruction of the TMJ by Chondro-Ossous graft from iliac crest after reconstruction of the glenoid fossa by cartilage from the ear and reconstruction of zygomatic arch by bone graft from iliac crest.

Experimental studies on Iris Monkeys or Rabbit were of great value for application of these new surgical procedures on humans.

All these procedures and techniques did great progress to surgery of the TMJ and also we got the ability to understand the pathology of these diseases.

We hope to present to our colloquies worldwide the fruit of our long and valuable experience and to share with them this knowledge and experience and we hope we did contributions to science.



*3 skulls, first one rabbit skull, second Monkey skull & human skull for my research and clinical application in TMJ Surgery.*

## Contents

Preface.....	VII
History of Maxillofacial Surgery .....	XI
Introduction.....	XVII
<b>Chapter 1 Basic Science.....</b>	<b>1</b>
Development of the TMJ .....	3
Anatomy & Physiology of TMJ .....	6
Ligaments of the TMJ .....	10
Functional Movements of the TMJ .....	11
Nerve Supply.....	12
Blood Supply.....	12
Articular Remodeling.....	12
Growth of TMJ .....	13
The Condylar Growth Centre Theory .....	14
The Functional Matrix Theory .....	15
Post Natal Growth.....	16
Structure of Adult Joint.....	16
References.....	17
<b>Chapter 2 Animal Models and Experimental Studies .....</b>	<b>19</b>
Requirements of Animal Model.....	21
Anatomy of TMJ of Macaca Iris Monkey .....	22
The Rabbits TMJ Specifications.....	24
References.....	26

<b>Chapter 3 TMJ Disease .....</b>	<b>27</b>
Congenital Disease of TMJ Due to Disturbance in Development and Growth of the Condyle.....	29
Hypoplasia of the Condyle.....	29
Condylar Hyper Plasia .....	33
Traumatic Injuries of the Condyle .....	35
Degenerative Disease of TMJ .....	39
A-Osteoarthritis of the TMJ .....	39
Rheumatic Disease of the TMJ .....	42
Infective and Septic Arthritis of TMJ .....	46
Microbiological Causes.....	51
Pathogenesis .....	53
Functional Causes .....	54
Disturbance of Function, Temporomandibular Joint Dysfunction (TMD) .....	54
Loss of Function.....	72
Tumors of the TMJ .....	75
References .....	80
 <b>Chapter 4 Surgical Reconstruction of the TMJ for Chronic and Acute Subluxation &amp; Acute and Chronic Dislocation, Clinical and Experimental Studies.....</b>	 <b>83</b>
Methods of Treatment.....	88
Conservative Techniques .....	89
Surgical Techniques .....	89
Surgical Reconstruction of the TMJ (Kummoona Technique).....	94
Surgical Release of Delayed Dislocation of Condyle and Stretched Capsule.....	96
Injection of the Lateral Pterygoid Muscle by BOTOX.....	96



Modified Manual Reduction of Acute Dislocation.....	97
Experimental Study.....	101
References.....	105

## **Chapter 5 Total Replacement of the TMJ by Prosthesis (Kummoona Prosthesis) .....109**

Ankylosis of the TMJ.....	113
Morphological Changes of the Facial Skeleton with TMJ Ankylosis.....	114
Surgical Access to TMJ .....	119
Reconstruction with 2-Part Prosthesis .....	123
Design of the 2-Part Chrome Cobalt Prosthesis of the TMJ.....	123
Experimental Studies on Monkeys for 2-Part Prosthesis.....	124
Results of Experimental Studies .....	126
Postmortems Studies .....	127
Clinical Application and Results of the 2-Part Prosthesis in the TMJ...	131
Fibrous Band between the Top Prosthesis and Lower Prosthesis.....	135
References.....	137

## **Chapter 6 Reconstruction of the TMJ by Chondro-Ossous Graft (Kummoona Graft) in Children, Clinical & Experimental Studies .....139**

Experimental Studies on Rabbits .....	143
Result of Experimental Studies.....	144
Postmortem and Cytological Studies of Chondro-Ossous Graft.....	145
Clinical Cases.....	148
The Impact of Traumatic Injuries to the TMJ in Children.....	154
Principle of Managements of Ankylosed TMJ in Children .....	155
Clinical Features of First Arch Dysplasia Syndrome or Hemi Facial Micro Somia.....	155
Steps Required for Surgical Managements of Hemi Facial Micro	

Somia.....	156
References.....	165
<b>Chapter 7 Reconstruction of the TMJ by Temporalis Muscle and Sialastic Implant.....</b>	<b>167</b>
Temporalis Muscle Flap for Treatment of TMJ Ankylosis .....	169
Reconstruction of the TMJ by Sialastic (Rubber Silicone) Implant .....	173
References.....	177
<b>Chapter 8 Re-implantation of the Condyle after Tumor Surgery.....</b>	<b>179</b>
References.....	186
<b>Chapter 9 Growth, Repair and Remodeling Achieved by Mesenchyme Stem Cells of the Chondro-Ossous Graft used for Reconstruction of the Temporo-Mandibular Joint.....</b>	<b>187</b>
Experimental Studies .....	191
Results of the Experiment .....	192
Postmortem and Histological Studies .....	192
Clinical Application .....	197
References.....	205